

# FLOW ASSESSMENT THROUGH METALLIC STENT USING PC-MRA

Andrea D. Holton\*, Edward G. Walsh\*,  
Ramakrishna Venugopalan \*\*, Andreas S. Anayiotos \*

Department of Biomedical Engineering\*  
University of Alabama at Birmingham,  
Birmingham, Alabama 35294-4440  
Codman and Shurtleff, a J&J Company\*\*  
Raynham, Massachusetts 02767-0350

## Introduction

Many investigators have compared magnetic resonance Angiography (MRA) with other imaging modalities in hopes of evaluating the accuracy of this non-invasive technique. Fayad et al (2000) found a good correlation of the coronary lumen between a high resolution free breathing black blood MRA and the conventional x-ray Angiography. The characterization of the plaque distribution within the lumen could lead to the intervention of further cardiac events. The successful implementation of this technology enables the detection of coronary wall thickness and area [2]. Typical plaque constituents including epicardial fat may increase the signal from even a three-dimensional volume technique [3].

While much progress has been achieved using phase velocity mapping, in many cardiovascular applications, success in quantitative flow measurement through a stent has been limited. Many investigators have examined different materials and geometries in the optimization of stent function and geometry. Stainless steel alloys create artifacts or signal voids prohibiting proper lumen visualization. Lethoinmonneir et al (1999) studied the proximity of the signal loss with a range of velocities in relation to two stainless steel stents. They were able to quantify a boundary from which signal loss was present. As the flow was increased, the length of the corresponding artifact also increased.

Nickel-Titanium alloys have been proven to be more MRI compatible with greatly decreased incidence of heating [5], dislocation [6] and artifact production [7].

Three evaluations of MRA thought implanted devices showed promise and validate the need for more MR-compatible implants. Langerak et al (1999) examined MRA through a coronary artery bypass grafts; their studies focused on the changes in technique to improve assessment of the graft function and morphology. They concluded that navigator-gated three-dimensional MRA may be the most accurate method for evaluating the severity of graft stenosis. Experimentation with MRA through a metallic implant has shown promise, especially in the work done by Kuehne et al; (2001) who were able to assess the flow accurately through a stent in the pulmonary vein and to compare these flow volumes with the stroke volumes in the left and right ventricles. There was not a statistical difference in the measurements. Success in measuring flow with phase contrast MRA through renal copper stents with full lumen

visualization demonstrates the feasibility of this non-invasive technique over the gold standard x-ray Angiography [10].

The aforementioned studies, combined with our study validate the promise of using MRI as an accurate tool in the prognosis of stenosed vasculature in interventional medicine. The aim of this work was to phase velocity map both at constant and pulsatile flows at 4.1T to determine the feasibility of flow measurement through such stents in vivo.

## Materials and Methods.

Phase-velocity mapping at 4.1T was used for a more clinically applicable study of the stent. Initially phase-velocity mapping was used over a range of constant flows created by a gravity feed. The volume rates measured by a bucket stopwatch method ranged from 0-35 mL/s. The velocity coefficient is a user-input parameter in the pulse sequence at the magnet. Therefore, the phase shift is referred to as the input velocity. The phase shift equation relates the phase shift to the fluid velocity. The phase-mapped volume rate was calculated from the axial phase maps. The phase shift at each pixel in the lumen of the stent was used to calculate the velocity at each pixel. The field of view and the stent size determine the pixel area.

## Results and Discussion

Axial Phase maps of no, medium and high flows are shown in Figures 1-3. The velocity dependent phase shifts are expressed as radians as shown in color scale to the right. Device artifact was minimal in these studies as shown below. The values of from the axial maps compared with the bucket stopwatch method are shown in figure 4.

There are many possible sources of error when conducting a study. The signal from the flowing media can be decreased due to two factors: The phase cancellation within the voxel and the overall phase shift from a voxel containing flowing material [11]. Nagel et al (1999) attributes the discrepancy between their MRA data and intravascular ultrasound (IVUS) to low spatial and temporal resolution, a decrease in cardiac output and coronary flow due to breath holding and the tendency of the heart rate to decrease during an invasive procedure [12].

Investigations of the effect of temperature on the viscosity of the media have shown a strong correlation of a few degrees in temperature changing the viscosity by approximately 20%.

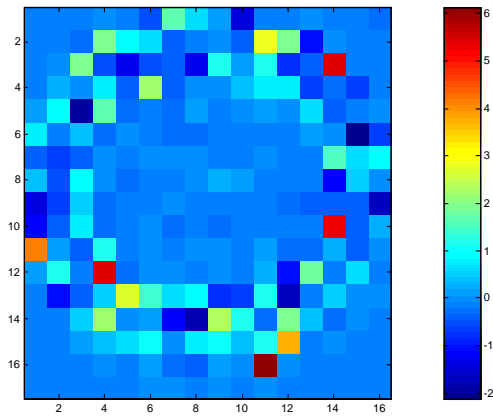


Figure 1. Axial Phase Map at 0 (mL/s).

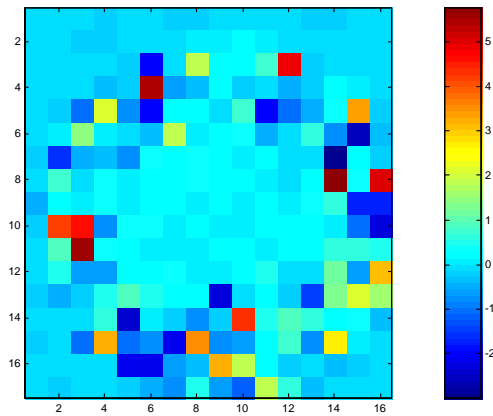


Figure 2. Axial Phase Map at 8.06 (mL/s).

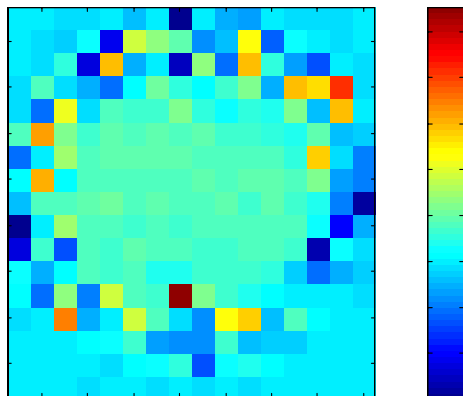


Figure 3. Axial Phase Map at 30.98 (mL/s).

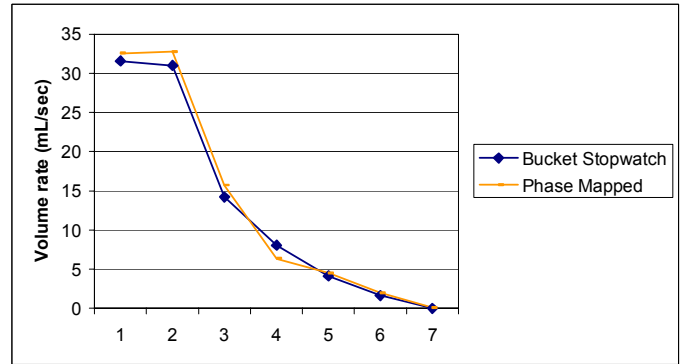


Figure 4. An illustration of the correlation of the constant flow phase maps to the laboratory calibration.

#### References:

1. Fayad. et al, 2000, "Noninvasive in vivo human coronary artery lumen and wall imaging using black-blood magnetic resonance imaging," *Circulation*, Volume 102, pp. :06-510.
2. Botnar et al, 2000, "Noninvasive coronary vessel wall and plaque imaging with magnetic resonance imaging. ", *Circ.* 102:2582-2587.
3. Stuber et al, 2001. "Three-dimensional high-resolution fast spin-echo coronary magnetic resonance Angiography," *Magnetic Resonance in Medicine*, Volume 445, pp.206-211.
4. Lethoinmonnier et al, 1999, "Error assessment due to coronary stents in flow-encoded phase contrast MR Angiography: a phantom study," *Journal of Magnetic Resonance Imaging*, 10:899-902.
5. Strolm et al, 1999, "Safety of Implantable Coronary Stents During 1H-magnetic Resonance Imaging at 1.0 and 1.5T," *J Cardiovascular Magnetic Resonance*, Volume 1(3), pp. 239-245.
6. Strouse P. et al, 1996, "Magnetic Deflection Forces From Atrial Septal Defect and Patient Ductus Arterious-occluding Devices, Stents, and Coil Used in Pediatric Age Patients," *Am J Cardiology*, Volume 78(4), pp. 490-491.
7. Hilfiker P. et al, 1999, "Plain and Covered Stent-grafts: In Vitro Evaluation of Characteristics at Three-dimensional MR Angiography," *Radiology*, Volume 211, pp 693-697.
8. Langerak, S. et al, 1999, "Evaluation of Coronary Artery Bypass Grafts by Magnetic Resonance Imaging," *Journal of Magnetic Resonance Imaging*, Volume 10, pp. 434-441.
9. Kuhne T et al, 2001, "Sequential Magnetic Resonance Monitoring of Pulmonary Flow with Endovascular Stents Placed across the Pulmonary Valve in Growing Swine," *Circulation*, Volume 104, pp. 2363-2368.
10. Buecker X. et al, 2002, "Artifact-free in-stent lumen visualization by standard magnetic resonance Angiography using new metallic magnetic resonance imaging stent," *Circulation*, Volume 105, pp. 1772-1775.
11. Nayler, G. et al, 1986, "Blood flow imaging by cine magnetic resonance," *J Comput Assist Tomog.* Volume 10, pp.715-722.
12. Nagel, E. et al, 1999, "Noninvasive determination of coronary blood flow velocity with magnetic resonance imaging: comparison of breath-hold and navigator techniques with intravascular ultrasound," *Mag Reson Med*, Volume 4, pp.544-549.