

Intestinal Protozoa Medical Microbiology 201

A wide variety of protozoa inhabit the intestinal tract of humans (Box). Almost all of these organisms are transmitted by a **fecal-oral** route (Figure). Fecal-oral transmission involves the ingestion of food or water contaminated with **cysts**. The cysts are excreted with the feces and are somewhat resistant to the environment. After ingestion by an appropriate host, the cysts transform into **trophozoites**, which are motile forms inhabiting the intestinal tract. During the trophic phase the parasite increases in size and undergoes asexual replication. Some of the trophozoites will develop into cysts that are passed in the feces, thus completing the life cycle.

Situations which will lead to food or water being contaminated by fecal matter will promote the transmission of these infections (see transmission factors). In general, the most common mode of transmission involves close personal contact combined with poor personal hygiene. Control activities focus on the avoiding the ingestion of material contaminated with feces. Health promotion and education aimed at improving personal hygiene (eg., hand-washing, food handling, sanitation, etc) are effective at reducing person-to-person transmission.

Intestinal Protozoa

Ameba:

- ***Entamoeba histolytica***
- *Entamoeba dispar*
- *Entamoeba coli*
- *Entamoeba hartmanni*
- *Endolimax nana*
- *Iodamoeba bütschlii*

Flagellates:

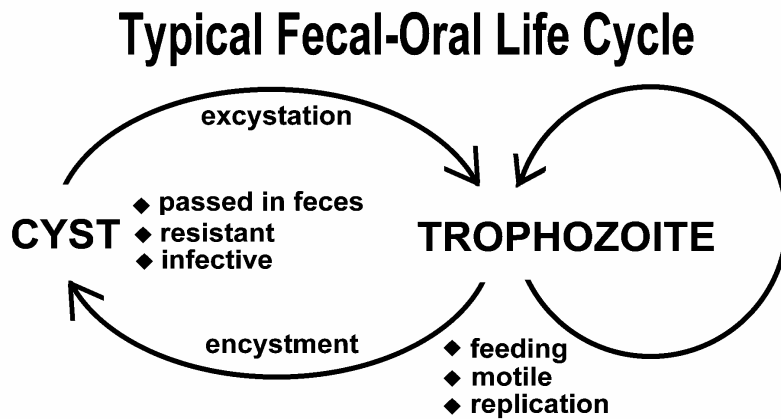
- ***Giardia lamblia***
- *Dientamoeba fragilis*
- *Chilomastix mesnili*
- *Trichomonas hominis*

Apicomplexa:

- ***Cryptosporidium hominis***
- ***Cryptosporidium parvum***
- *Cyclospora cayetanensis*
- *Isospora belli*

Other:

- *Blastocystis hominis*
- *Balantidium coli*



Transmission Factors

- poor personal hygiene
 - children (eg, day care centers)
 - food handlers
- developing countries
 - poor sanitation
 - often endemic
 - travelers diarrhea
- water-borne epidemics
- male homosexuality (oral-anal contact)
- zoonosis?
 - *Entamoeba* = no
 - *Cryptosporidium* = yes
 - *Giardia* = controversial

The majority of the intestinal protozoa are non-pathogenic or cause a very mild disease. *Entamoeba histolytica* is an exception and can be a highly virulent and lethal pathogen. *Giardia lamblia* is never mortal, but can cause severe diarrhea and a wasting syndrome. *Cryptosporidium*

and other apicomplexa normally cause a transient diarrhea and do not cause serious disease. However, they can result in a severe and potentially life-threatening diarrhea in AIDS patients or other immunocompromised individuals.

Giardiasis

Giardia lamblia is a protozoan parasite of the small intestine. It has a worldwide distribution. However, the prevalence is higher in tropical and developing countries. It is the most common protozoan isolated from human stools. The incidence is estimated at 200 million cases per year. *Giardia* is non-invasive and often results in an asymptomatic infection. Symptomatic giardiasis is typically characterized by acute diarrhea.

Life cycle. *Giardia* exhibits a typical fecal-oral transmission cycle and infection is acquired by ingesting cysts. Factors leading to contamination of food or water with fecal material are usually associated with transmission. For example, giardiasis is especially prevalent in children and particularly those children in institutions or day-care centers. In developing countries, poor sanitation may contribute to the higher levels of giardiasis and water-borne outbreaks due to inadequate water treatment have also been documented. Backpackers in areas of no human habitation are believed to acquire from drinking from streams and some data suggest that beavers are reservoir. However, the zoonotic transmission of *Giardia* is controversial and has not been documented.

Following passage through the stomach, the trophozoite emerges from the cyst. Trophozoites reside in the upper portions of the small intestine and reproduce by binary fission. On the ventral side of the trophozoite is a concave structure called the **adhesive disk**. The adhesive disk functions in attachment of the trophozoite to the intestinal epithelial cells. Some of the trophozoites will undergo an encystation process which results in the detachment from the intestinal epithelial and the maturation into cysts which are passed in the feces.

Clinical manifestations and pathogenesis.

Symptoms associated with giardiasis range from asymptomatic to acute gastrointestinal manifestations. Generally the symptoms are more severe the first time a person experiences giardiasis and children are at the greatest risk for contracting clinical giardiasis. In the majority of untreated patients the infection resolves spontaneously, but it can become chronic and last for several months or even years in rare cases. The acute symptoms are a sudden explosive, watery, foul-smelling diarrhea (see box). The stools are generally describes as loose, bulky, frothy, and/or greasy with no blood or mucous. This is sometimes accompanied by nausea, colicky epigastric pain, vomiting, and/or prolonged belching.

Acute Symptoms

- 1-2 week incubation
- sudden explosive, watery diarrhea
 - bulky, frothy, greasy, foul-smelling stools
 - no blood or mucus
- upper gastro-intestinal uneasiness, bloating, flatulence, belching, cramps, nausea, vomiting, anorexia
- usually clears spontaneously (undiagnosed), but can persist or become chronic

The acute stage usually resolves spontaneously in 3-4 days and is often not recognized as giardiasis. Occasionally an acute infection will persists leading to malabsorption, steatorrhea (exces-

sive loss of fat in the feces), debility (loss of strength) and weight loss. Acute infections can also develop into long-standing subacute or chronic infections characterized by recurrent brief episodes of gastro-intestinal symptoms. Anorexia accompanied by marked weight loss is sometimes associated with chronic infections.

The disease manifestations appear to be related to malabsorption, particularly of fat and carbohydrates. However, the specific mechanisms of *Giardia* pathogenesis are not known. No specific virulence factors have been identified. Attachment of large numbers of trophozoites to the brush border could produce a mechanical irritation or mucosal injury. In addition, normal villus structure is affected in some patients. For example, villus blunting (atrophy) and crypt cell hypertrophy and an increase in crypt depth have been observed to varying degrees. The increase in crypt cells will lead to a repopulation of the intestinal epithelium by relatively immature enterocytes with reduced absorptive capacities. An increased inflammatory cell infiltration in the lamina propria has also been observed and this inflammation may be associated with the pathology. *Giardia* infection can also lead to lactase deficiency, as well as other enzyme deficiencies, in the microvilli. This reduce digestion and absorption of solutes may contribute to an osmotic diarrhea. The *Giardia*-induced lactose intolerance may persist for a variable time following elimination of the parasite. Thus far, no single virulence factor or unifying mechanism explains the pathogenesis of giardiasis.

Diagnosis and treatment. Diagnosis is confirmed by finding cysts or trophozoites in feces or in duodenojejunal aspirates or biopsies. Stool examination is the preferred method for *Giardia* diagnosis. However, detection of the parasites can be difficult since *Giardia* does not appear consistently in the stools of all patients. Some patients will express high levels of cysts in nearly all the stools, whereas others will only exhibit low parasite counts in some of the stools. In addition, parasites are easier to find during acute infections than chronic infections. Aspiration and biopsy may also fail to confirm the infection due to patchy loci of infection, and some question the usefulness of these invasive procedures.

Diagnosis can also be made by examining duodenal fluid for trophozoites. Duodenal fluid is obtained by either intubation or the Enterotest[®] (also called 'string test'). The Enterotest[®] consists of a gelatin capsule containing a nylon string of the appropriate length. The free end of the string is taped to the patient's face and the capsule is swallowed. After four hours to overnight the string is retrieved and the bile-stained mucus on the distal portion of the string is scraped off and examined by both wet mount and permanent staining.

Infected individuals should be treated since *Giardia* can persist and lead to a chronic disease involving malabsorption and weight loss. Metronidazole (Flagyl[®]), although not licensed in the United States for giardiasis, effectively clears the parasite (cure rates approximately 85%) and is the drug of choice. Other effective drugs include: quinacrine (Atabrine[®]), tinidazole (Fasigyn[®]), furazolidone (Furoxone[®]), and paramomycin (Humatin[®]). Tinidazole is effective as a single two gram dose. Paramomycin is not absorbed and may be useful during pregnancy.

Amebiasis

E. histolytica is cosmopolitan in distribution. However, it is more common in tropical

countries with poor sanitary conditions. It is estimated that up to 10% of the world's population may be infected with *E. histolytica* and in many tropical countries the prevalence may exceed 30%. Humans are the only host of *E. histolytica* and there are no animal reservoirs.

Life Cycle. The infection is acquired when cysts are ingested. The factors contributing to infection are the similar to other organisms transmitted by the fecal oral-route. Excystation takes place in the intestines after passing through the stomach. A trophozoite emerges through the disrupted cyst wall and begins to replicate by binary fission. This trophic period occurs on the mucosa of the large intestine. Some of the trophozoites will not replicate and undergo encystation leading to the production of cysts. Up to 45 million cysts can be passed per day in the feces of an infected person.

Pathogenesis. *E. histolytica* is a **facultative pathogen**. Normally *E. histolytica* lives in the human large intestine and feeds on the bacterial fauna. During this stage persons are often asymptomatic or exhibit symptoms such as a non-dysenteric diarrhea, cramps, or abdominal discomfort (Box). Many individuals will clear the infection spontaneously in 6-12 months.

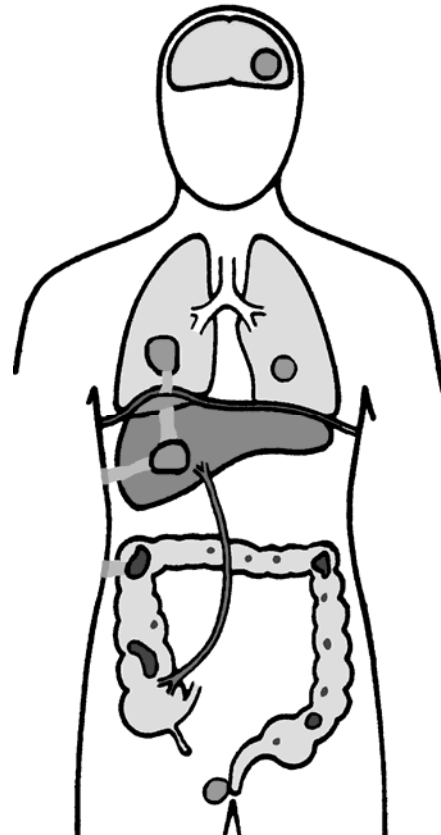
PATHOGENESIS OF AMEBIASIS

non-invasive

- ameba colony on mucosa surface
 - asymptomatic cyst passer
 - non-dysenteric diarrhea, cramps, abdominal discomfort

invasive

- necrosis of mucosa → ulcer
 - dysentery
 - hematophagous trophozoites
- ulcer enlargement → colitis, peritonitis, occasional ameboma
- metastasis → extraintestinal amebiasis
 - dissemination primarily via blood-stream (eg., portal vein)
 - predominantly liver → amebic abscess
 - other sites infrequent (cutaneous, pulmonary)
 - ameba-free stools common



The parasite can also penetrate the intestinal mucosa and epithelial cells and cause severe disease. The initial stage of invasive disease is an ulceration of the colon. Trophozoites are able to kill host epithelial cells in a contact dependent manner and gain access to the lamina propria. In addition, the trophozoites begin to ingest host cells instead of bacteria. The ingestion of host cells is indicated by the presence of trophozoites containing erythrocytes, or **hematophagous** ameba.

During this phase the patient may exhibit dysentery and the feces may contain hematophagous trophozoites.

The trophozoites destroy and ingest host cells leading to ulcer enlargement below the epithelial layer producing a characteristic 'flask-shaped' ulcer. The dysentery will worsen as the lesions continue to expand both laterally and downward into the lamina propria. Ulcers can coalesce leading to sloughing off of large sections of the intestinal epithelium. Peritonitis will result if the ulcer spans the colon wall. Occasionally a tumor-like mass, known as an ameboma, will form in the intestinal wall. This severe pathogenesis is not advantageous for the parasite, since cysts are no longer produced after the ameba becomes invasive.

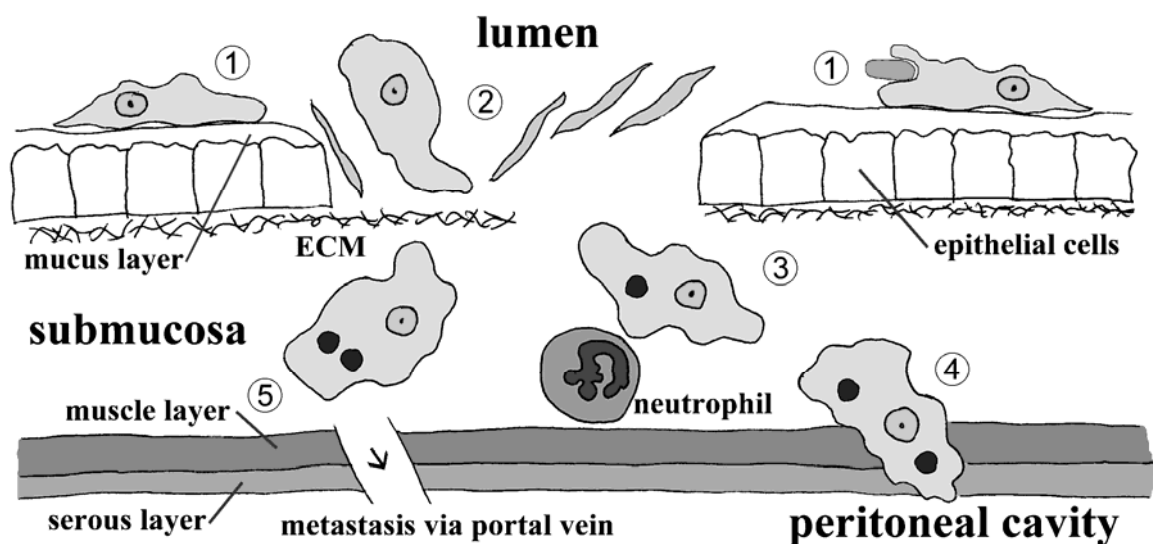
The ameba can also become extra-intestinal and metastasize to other tissues with the liver being the most commonly affect organ. This invasion of the liver is likely due to hematogenous spread via the portal vein. The lesions in the intestines and liver can also expand by a direct extension to the skin or lungs. Extraintestinal amebiasis is a relentless and progressive disease which will result in death if untreated.

Virulence factors. Approximately 85-90% of people infected with *E. histolytica* are asymptomatic carriers. Among the symptomatic patients only 10% will develop severe dysentery or invasive disease. Some of this difference in disease etiology can be explained by genetically distinct *E. histolytica* isolates (Table). Molecular, biochemical and immunological data indicate that *E. histolytica* actually consists of two distinct species: one is capable of causing an invasive disease and the other is non-pathogenic. The 2.2% difference in their rRNA sequences is approximately the same as the difference observed between mice and humans indicating that the two amebas are quite diverged.

Non-Invasive and Invasive Isolates of <i>Entamoeba histolytica</i>		
CRITERIA	NON-INVASIVE	INVASIVE
In Vitro Culture	xenic	axenic
ConA Agglutination	-	+
Complement Resistance	-	+
Zymodemes (isoenzymes)	I & III	II
Numerous Antigenic Differences (eg., GIAP Epitopes)	1-2	1-6
rRNA Sequence	2.2% sequence diversity	
RFLP/DNA Probes	B133, cEH-NP1	P145, cEH-P1

The non-pathogenic form has been named *E. dispar*. Immunological or molecular probes are needed for the definitive diagnosis of *E. dispar* and *E. histolytica* since the two species are morphologically identical. Persons infected with *E. histolytica*, as document by molecular or immunological methods, do not always develop severe disease and many are healthy cyst passers. Pathogenicity refers to the ability of an organism to cause disease and does not necessarily mean that pathology will result. Virulence, a term that is often used interchangeably with pathogenicity, refers to the degree of pathology that can be caused by the organism. Therefore various degrees of virulence may be exhibited by a pathogen depending upon conditions.

Factors that are associated with the invasive disease and subsequent pathology include: the contact dependent cell killing exhibited by *E. histolytica*, disruption of tissues, and a resistance to the host's immune response (Figure). *E. histolytica* can destroy cells within 5 minutes after adhering to them. The exact molecular mechanisms contributing to the pathogenesis and virulence of *E. histolytica* are not understood though. The nature of protective immune responses against invasive disease are not known. In summary, *E. histolytica* is a facultative pathogen capable of cause severe and mortal disease. *E. dispar* is a morphologically identical species which is non-pathogenic. The virulence of *E. histolytica* is associated with its ability to kill host cells in a contact dependent manner and to disrupt host tissue. Some possible factors that may be associated with virulence have been identified. However, more work is needed to demonstrate their role(s) in pathology.



Diagnosis and treatment. Definitive diagnosis of amebiasis requires the demonstration of *E. histolytica* cysts or trophozoites in feces or tissues. Stool specimens should be preserved and stained and microscopically examined. Cysts will tend to predominate in formed stools and trophozoites in diarrheic stools. Fresh stools can also be immediately examined for motile trophozoites which exhibit a progressive motility. Sigmoidoscopy may reveal the characteristic ulcers, especially in more severe disease. Aspirates or biopsies can also be examined microscopically for trophozoites. *E. histolytica* and *E. dispar* cannot be distinguished on morphological criteria. Antigen detection kits are available for the positive identification of these species.

Serology is especially useful for the diagnosis of extraintestinal amebiasis. Greater than 90% of patients with invasive colitis and liver abscesses exhibit serum antibodies against *E. histolytica*. However, the antibodies can persist and distinguishing past and current infections may pose problems in endemic areas. Non-invasive imaging techniques (eg., ultrasound, CT, MRI) can be used to detect hepatic abscesses.

Several drugs are available for the treatment of amebiasis and the choice of drug(s) depends

on the clinical stage of the infection. The prognosis following treatment is generally good in uncomplicated cases. In cases where *E. histolytica* is confirmed or the species (ie, *dispar* or *histolytica*) is unknown, asymptomatic cyst passers should be treated to prevent the progression to severe disease and to control the spread of the disease. However, in many endemic areas, where the rates of reinfection are high and treatment is expensive, the standard practice is to only treat symptomatic cases. Metronidazole, or tinidazole (if available), is recommended for all symptomatic infections. This treatment should be followed by or combined with luminal anti-amebic drugs, such as iodoquinol, paromomycin, or diloxanide furoate, to eliminate the cysts.

Cryptosporidiosis

The coccidia are apicomplexan parasites. Like other apicomplexans (eg., malarial parasite), they exhibit complex life cycles characterized by intracellular stages. The defining characteristic of the apicomplex are specialized organelles found in some life cycle stages that function in the invasion of host cell. The defining characteristic of the coccidian is a thick walled oocyst stage that is excreted with the feces. A few coccidian species infect humans and several are of veterinary importance. *Cryptosporidium*, *Cyclospora*, *Isospora* carry out their entire life cycle within the intestinal epithelial cells of the host and are transmitted by the fecal-oral route. *Toxoplasma* has a more complicated life cycle involving tissue stages in the human host while the intestinal stages are found in cats.

Coccidia Infecting Humans

- *Isospora*
- *Cryptosporidium*
- *Cyclospora*
- *Toxoplasma*

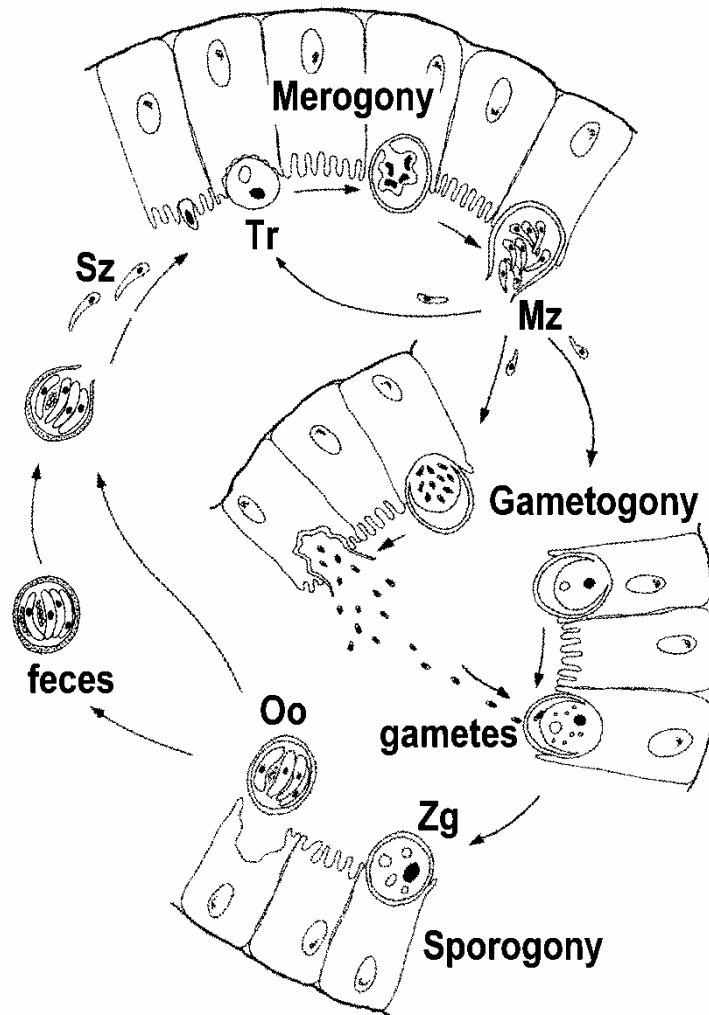
Cryptosporidium was first described in 1907 and has been found in a wide variety of animals. The first human cases of cryptosporidiosis were reported in 1976. Initially it was believed to be a rare and exotic infection. However, it is now recognized as a common human pathogen and a frequent cause of diarrhea in humans. In immunocompetent individuals this diarrhea is self-limiting and last about two weeks. The disease is quite serious and potentially life-threatening in immunodeficient patients (especially AIDS) and is characterized by a profuse watery diarrhea.

Life cycle. The infection is acquire through the ingestion of sporulated oocysts. Each oocyst contains four sporozoites. After passage through the stomach the sporozoites emerge from the oocyst and attach to intestinal epithelial cells. In contrast to other coccidia, *Cryptosporidium* sporozoites do not invade the enterocytes. Instead they induce an extension and fusion of the microvilli resulting in the parasite becoming surrounded by a double membrane of host origin. Even though the parasite is surround by host membranes it is not intracellular and is referred to as being 'extracytoplasmic'. A junction, called the 'feeder organelle' or the 'adhesion zone', forms between the parasite and the host enterocyte. The parasite, now called a trophozoite, likely derives nutrients from the host cell via this junction.

Trophozoites undergo an asexual replication (ie, merogony) and produce 4-8 merozoites which are released into the intestinal lumen. These merozoites infect new intestinal epithelial cells and undergo additional rounds of merogony. The interaction of the merozoites with the intestinal epithelial cells is the same as the interactions between sporozoites and epithelial cells. In immunocompetent individuals the immune response will limit the number of rounds of

merogony leading to a self-limiting disease. The increased severity of the disease in immunocompromised patients is due in part to their inability to limit these additional rounds of merogony.

As an alternative to merogony, the merozoites can develop into either macro- or microgametocytes following the infection of an enterocyte. Microgametogenesis involves several rounds of replication followed by the release of numerous microgametes into the intestinal lumen. The microgametes will seek out and fertilize macrogametes still attached to the intestinal epithelial cells. The resulting zygote undergoes sporogony resulting in the formation of sporulated oocysts. The sporulated oocysts are excreted with the feces and are immediately infections.



An autoinfection in which the sporozoites emerge within the intestinal lumen of the same host is also possible. Thick-walled and thin-walled oocysts have been noted and it is believed that the thin wall oocysts are responsible for the autoinfection and the thick-walled oocysts are more environmentally robust and responsible for person-to-person transmission. This autoinfection may also contribute to the increased disease severity in immunocompromised patients in that immunocompetent persons may be more resistant to the autoinfection.

Transmission and molecular epidemiology. Although the life cycle is more complex, *Cryptosporidium* exhibits a typical fecal-oral transmission. Therefore, the risk factors of transmission for *Cryptosporidium* are similar to other fecal-oral diseases. However, waterborne cryptosporidiosis outbreaks have been especially notable. The most infamous is an outbreak in Milwaukee during the spring of 1993 in which an estimated 400,000 people developed symptomatic cryptosporidiosis (MacKenzie et al, New Eng. J. Med. 331:161, 1994).

Water Borne Outbreaks of Cryptosporidiosis in the USA

Year	Location	% Inf.	suspected cause(s)
1984	Braun Station, TX	0.2	sewage contaminated well
1987	Carrolton, GA	1.3	water-treatment deficiencies
1988	Los Angeles, CA	-	inoperative swimming pool filters
1991	Pennsylvania	0.06	water-treatment deficiencies
1992	Jackson County, CO	1.5	water-treatment deficiencies
1992	Lane County, OR	-	oocysts in filter washback water
1993	Madison, WI	-	fecal accident in swimming pool
1993	Milwaukee, WI	40.3	spring thaw, water-treatment deficiencies
1994	Clark county, NV	0.008	fecal accident in swimming pool

Modified from Graczyk et al (1997) Parasitology Today 13:348

Many features of *Cryptosporidium* and its transmission contribute to this association with waterborne outbreaks (box). In particular, the small size and robustness of the oocyst make it difficult to remove during water treatment processes. Furthermore, many of the outbreaks have occurred in rural communities and it is felt that the source of the infection is from cows.

- small size of oocysts (4-5 μm)
- reduced host specificity and monoxenous development
- close associations between human and animal hosts
- large number of oocysts excreted (up to 100 billion per calf per day)
- low infective dose (<30)
- robust oocysts; resistant to chlorine
- infectious sporulated oocysts excreted in feces

Despite the impressiveness of some waterborne outbreaks, human-to-human transmission is probably the predominant mode of transmission. For example, asymptomatic infected children are common, secondary cases in households are high, and outbreaks tend to occur in hospitals, institutions and day care centers. All of these are situations in which typical fecal-oral transmission is high.

Molecular studies have revealed two primary genotypes isolated from humans. Genotype 1 has only been isolated from human sources and is non-infective for mice and calves. Genotype 2 has been isolated from both animal (bovine and ovine) and human sources and is infective for mice and calves. Based upon these and other biological differences it has been proposed to rename genotype 1 as *Cryptosporidium hominis* (Morgan-Ryan et al, J. Euk. Microbiol. 49:433, 2002).

Genetic data imply that there are two distinct transmission cycles in humans involving

two different populations of *Cryptosporidium*: 1) an exclusively anthroponotic (ie, human-to-human) cycle caused by genotype 1 (or *C. hominis*) and 2) a zoonotic cycle caused by genotype 2 (or *C. parvum*). The zoonotic cycle would initially involve transmission from animals (eg, cattle or sheep) to humans and then subsequently human-to-human transmission and possibly a human-to-animal transmission. Both genotypes have been demonstrated to be the etiological agent in waterborne outbreaks. Waterborne outbreaks linked to *C. hominis* are likely due to contamination of water with human sewerage, whereas waterborne outbreaks associated with *C. parvum* (genotype 2) are likely due to contamination of water with cow or sheep feces.

Pathogenesis. The most common clinical manifestation of cryptosporidiosis is a mild to profuse watery diarrhea. This diarrhea is generally self-limiting and persists from several days up to one month. Recrudescences are common. Abdominal cramps, anorexia, nausea, weight loss and vomiting are additional manifestations which may occur during the acute stage. The disease can be much more severe for persons with AIDS which manifests as a chronic diarrhea lasting for months or even years. Some AIDS patients exhibit a fulminant cholera-like illness which requires intravenous rehydration therapy. The fatality rate can be quite high in these fulminant cases.

SYMPTOMS	%
Watery Diarrhea	93
mean=12d; med=9d (1-55d)	
mean=19/d; med=12/d (1-90)	
39% recurred after days free	
Abdominal Cramps	84
Weight Loss	75
med=10lb (1-40lb)	
Fever	57
med=38.3 (37.2-40.5)	
Vomiting	48

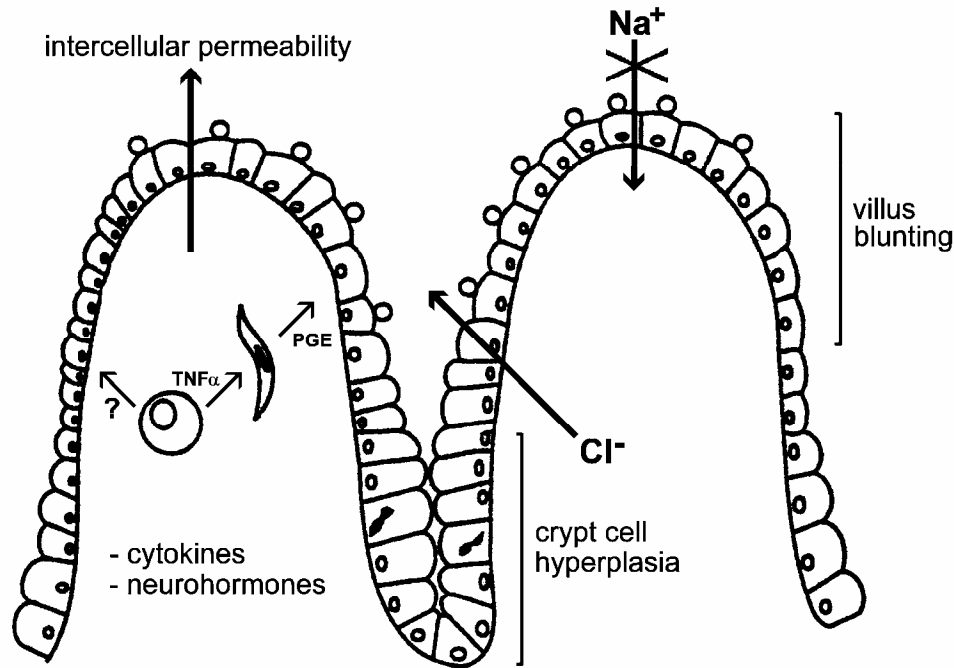
Diarrhea can have osmotic, inflammatory, or secretory components (see Box). The watery nature of the diarrhea associated with *Cryptosporidium* infections has suggested the presence of an enterotoxin. However, there is no evidence for a toxin-mediated secretory diarrhea despite efforts to identify such a toxin. Experimental evidence does suggest that glucose-coupled Na⁺ absorption is decreased and Cl⁻ secretion is increased. Therefore, the diarrhea associated with *Cryptosporidium* appears to be primarily osmotic in nature.

Aspects of Diarrhea	
osmotic	<ul style="list-style-type: none"> • characterized by enterocyte malfunction, eg: <ul style="list-style-type: none"> ○ ↓ Na⁺ absorption ○ ↑ Cl⁻ secretion
inflammatory	<ul style="list-style-type: none"> • generally associated with invasion of the mucosa • inflammation of the lamina propria • leukocytes in the stools
secretory	<ul style="list-style-type: none"> • generally associated with bacterial enterotoxins • characterized by watery diarrhea

Associated with this disruption of enterocyte (i.e., intestinal epithelial cells) function is a blunting of the villi and crypt cell hyperplasia. A possible mechanism of pathogenesis is that the infection of intestinal epithelial cells with *Cryptosporidium* damages the enterocytes and eventually leads to their death. This triggers cell division in the crypt region (i.e., hyperplasia) to replace the damaged cells. The combination of destruction of absorptive cells at the tips of the villi and the increase in the Cl⁻-secreting crypt leads to an overall enhanced secretion.

In addition, an increased intercellular permeability and inflammation in the submucosal

layer (aka, lamina propria) has been associated with *Cryptosporidium* infection. These phenomenon could also contribute to the secretory process via cytokines and neurohormones. For example, macrophages secreting tumor necrosis factor-alpha (TNF- α) or other cytokines may stimulate fibroblasts and other cells in the lamina propria to secrete prostoglandins (PGE) and other products (eg., reactive oxygen intermediates). These products may then promote secretion and impair absorption.



Diagnosis and treatment. Coccidiosis is diagnosed by demonstrating oocysts in the feces. Acid-fast staining is the preferred method for coccidia which stain bright red. *Cryptosporidium*, *Cyclospora*, and *Isospora* are distinguished by size and oocyst structure. *Cyclospora* and *Isospora* do not uniformly take up the stain resulting in a mixture of unstained, partially stained and completely stained oocysts.

There is no completely satisfactory treatment for *Cryptosporidium*. It is hypothesized that the extracytoplasmic location of *Cryptosporidium* shelters it from drugs. Paromomycin has been used for the treatment of cryptosporidiosis, however, its efficacy is debated. Controlled studies indicate that paromomycin modestly suppresses parasitemia in immunocompromised individuals. Treatment of severe cryptosporidiosis should include supportive care (rehydration and nutritional support) and anti-motility agents.

Mark F. Wiser, Ph.D.
 Department of Tropical Medicine
 wiser@tulane.edu
<http://www.tulane.edu/~wiser/T2.html>